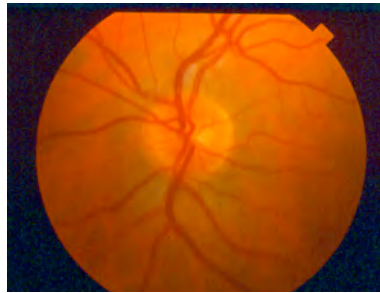
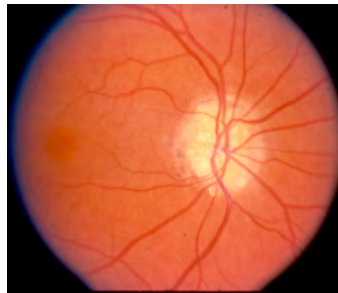


Optic Disc Drusen

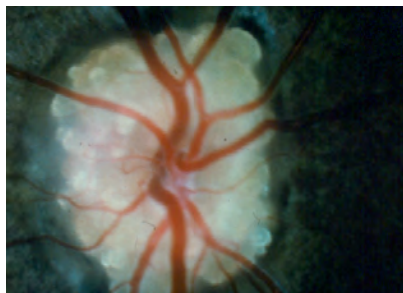
Your doctor has diagnosed you with optic disc drusen. Optic disc drusen are abnormal deposits of protein-like material in the optic disc – the front part of the optic nerve. We do not know the exact cause of optic disc drusen but they are thought to come from abnormal flow of material in optic nerve cells.



Normal Enlarged view of Optic Disc



Lumpy Appearance of Optic Disc

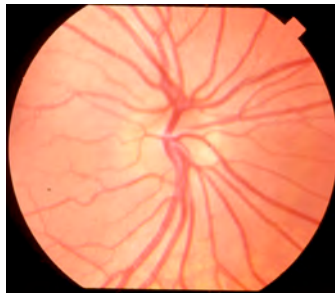

Optic Disc Drusen With Drusen

Optic disc drusen occur in about 1% of the population and are found more frequently in Caucasians. In three-

quarters of cases they appear in both eyes. Optic disc drusen may be inherited or may occur without any family history. Familial drusen are inherited as an autosomal dominant trait, which means your mother or father or child is likely to have the condition.

Optic disc drusen are usually not visible at birth and are rarely found in infants and children. The drusen tend to develop slowly over time as the abnormal material collects in the optic nerve head and calcifies. The average age when optic disc drusen first appear is about 12. Often, the optic disc has an unusual appearance, with multiple branches of the major blood vessels as they emerge on the disc.



Multiple Branches of Blood Vessels

As time passes, optic disc drusen can calcify and become more prominent. Optic disc drusen are rarely associated with any systemic disease or eye disease.

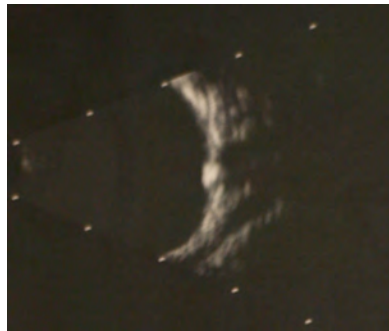Symptoms

Optic disc drusen often come to medical attention during a routine eye examination. Patients usually have no symptoms and do not notice any problem with their vision. Occasionally, patients may have flickering or graying out of vision that lasts a few seconds or they may notice subtle visual field loss. The elevation of the optic disc with drusen may be mistaken for papilledema, which is swelling of the

optic nerve from increased intracranial pressure. This prompts referral to a neurologist, neuro-surgeon, or even the emergency room.

Diagnosis

Optic disc drusen either can be buried within the substance of the optic nerve head or located superficially on the surface of the optic nerve head. When the drusen are superficial, they appear as glistening yellow bodies just below the surface of the optic nerve head and can be seen by ophthalmoscopic examination. When the optic disc drusen are buried deep in the disc, the drusen are hidden from direct view by the ophthalmoscope but can be identified by ultrasound.



Ultrasound Showing Large Druse

If the drusen have become calcified, they also can be detected with computer tomography (CT) scanning. Visual field testing is important to detect defects in peripheral vision.

Prognosis

Most patients with optic disc drusen retain normal central vision. However, over time 70% of patients lose some peripheral vision. The amount of peripheral visual field loss varies from none to severe constriction of the peripheral

visual field. The visual field should be followed periodically with formal visual fields testing. Patients with optic disc drusen may also be at an increased risk for developing non-arteritic anterior ischemic optic neuropathy (NAION), branch retinal vein occlusion (BRVO), and central retinal vein occlusion (CRVO).

Management and Treatment

There is no proven or standard treatment for optic disc drusen. Nevertheless, careful monitoring of the visual field is essential to detect progression of visual field loss. Rarely, a small area of new blood vessels called a choroidal neovascular membrane [CNV] can develop adjacent to the optic disc. A CNV has a tendency to bleed and cause sudden visual loss. Early detection of the presence of CNV is extremely important because prompt treatment can often prevent serious complications from bleeding.

Frequently Asked Questions

Why did I develop optic disc drusen?

Optic disc drusen are caused by an abnormal deposition of a protein-like material in the optic nerve. The cause of this material is unknown. In some individuals, the deposition of this material can be inherited, while in others it occurs without a family history.

How does my doctor diagnose this condition?

Your doctor can diagnosis this condition either by an ophthalmoscopic examination or with the aid of ultrasound or computer tomography (CT) scanning.

Will the drusen get worse?

The number and size of the optic disc drusen tend to increase over time.

Can this condition affect any of my family members?

Yes, optic disc drusen can occur as an inherited family trait and may affect first-degree relatives. Patients diagnosed with optic disc drusen should consider discussing their diagnosis with their family members so that they undergo screening evaluation. Optic disc drusen usually do not show up in Infants and children younger than 4 years

Should I let other physicians who may be caring for me or other family members know about my condition?

Yes, it would be helpful for other physicians who are involved with your care or the care of a family member to know that you have diagnosed with optic disc drusen. You should inform them that you do not have papilledema.

Is there anything I can do to prevent the drusen from getting worse?

No, there is no proven or standard way to prevent the optic disc drusen from increasing in size.

Is there any treatment for this condition?

No, there is no proven treatment for optic disc drusen at this time.

If there is no treatment for optic disc drusen, why should I have regular ophthalmic examinations?

Some patients with optic disc drusen may rarely develop a growth of new abnormal blood vessels (choroidal neovascularization) adjacent to the optic nerve, which may be prone to bleeding. If new blood vessels develop, they may need laser treatment to prevent bleeding. Periodic examination is recommended to detect this potentially serious complication. Additionally, regular visual field testing is necessary to track any progression of peripheral visual field loss.