


Anisocoria

Your doctor has noted that you have **anisocoria**, which means that the pupil in the right eye and left eye are not the same size. A small amount of anisocoria or difference in pupil size is normal. On some days, a person's right pupil might be larger than the left and on other days, the pupils might be the same size or the left might be larger than the right. But if more than a small difference in pupil size is present and persists, you may have a neurologic problem.



Anisocoria

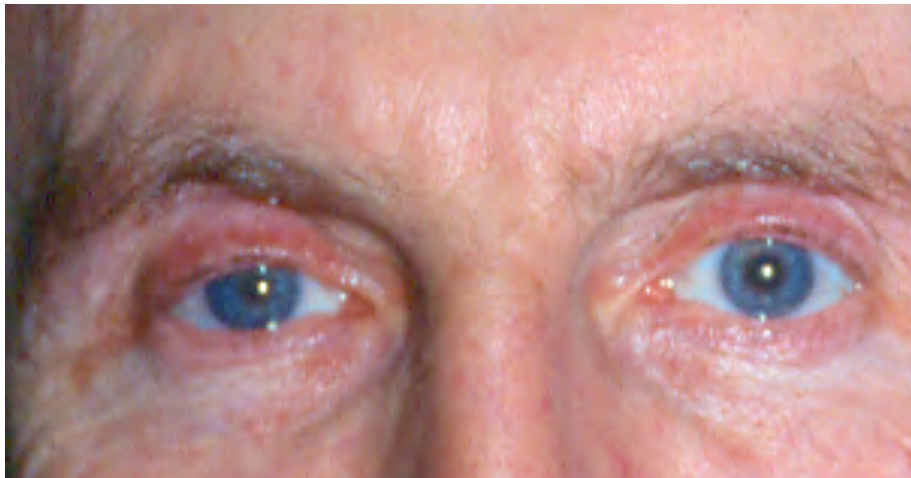The iris is the colored (brown, blue, etc.) portion of the eye and the pupil is the black, circular area in the center of the iris. The pupil is actually a hole in the iris which controls the amount of light that gets into the eye. In dim light, the hole, or pupil, gets larger (dilates) to let in more light, while in bright light, the pupil gets smaller (constricts) in order to protect the eye from too much light.

The size of the pupil is controlled by muscles in the iris – the iris dilator and the iris constrictor muscles. The muscles are controlled by nerves from the brain to the eye. Problems with these nerves cause the size of the pupil to be

abnormal. A problem with the nerve that normally dilates the pupil in the dark, causes a small pupil. A problem with the nerve that normally constricts the pupil, produces an abnormally large pupil.

An Abnormally Small Pupil

The nerve that dilates the pupil in the dark, the oculosympathetic nerve, also controls a little muscle that holds the eyelid open. When the oculosympathetic nerve is not working, the pupil on that side is abnormally small and the upper eyelid droops a bit. This is called **Horner Syndrome**.



Horner Syndrome


Although having Horner Syndrome by itself will not damage the eye or cause loss of vision, it may be a signal of damage to one of the structures along the nerve. The nerves that dilate the pupils in dark come in contact with many structures. They begin in the brain and pass down to the spinal cord. They exit from the spinal cord and run up over the lung and into the neck, where they travel with the carotid artery. They follow the carotid artery back into the

brain, from where they enter the eye and go to the dilator muscle of the iris. Damage anywhere along this path will cause Horner Syndrome. It is important to find out where the damage is and what is causing it because sometimes it can be serious. Examples of serious conditions causing Horner syndrome are a stroke in the brain or a tumor in the lung or a break in the wall of the carotid artery called a **carotid dissection**. In other cases, the Horner syndrome is due to birth trauma. Sometimes no cause can be found and the patient remains well.

Your doctor may do one or two eye drop tests to confirm that a Horner Syndrome is present and to determine the location of the nerve damage. Detailed radiologic studies, usually magnetic resonance imaging (MRI), are done to look at the places the nerves pass through for possible causes of the damage.

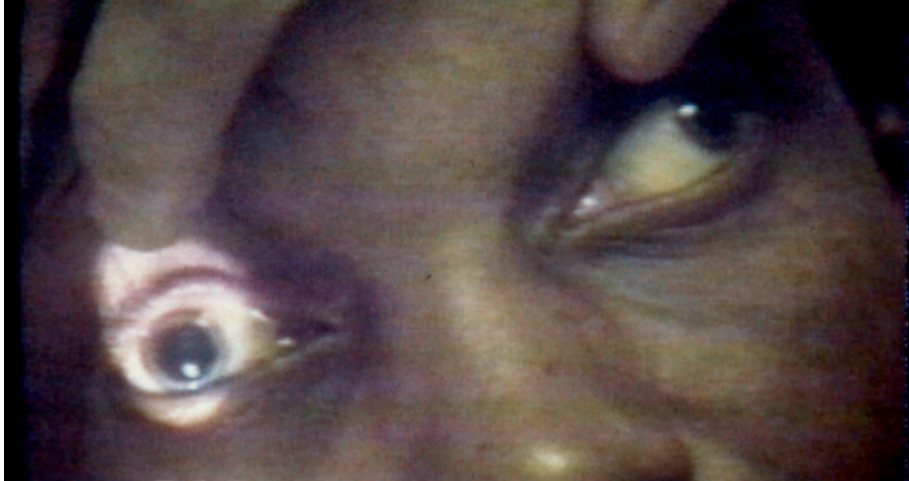An Abnormally Large Pupil

The nerve that goes to the constrictor muscle is part of the IIIrd cranial (oculomotor) nerve. The IIIrd cranial nerve controls several of the muscles that move the eye. It also controls the muscle that opens the eyelid and the muscle that constricts the pupil. A problem with the IIIrd nerve can result in a droopy eyelid, double vision and/or enlarged pupil.



IIIrd Nerve Damage – lid droop

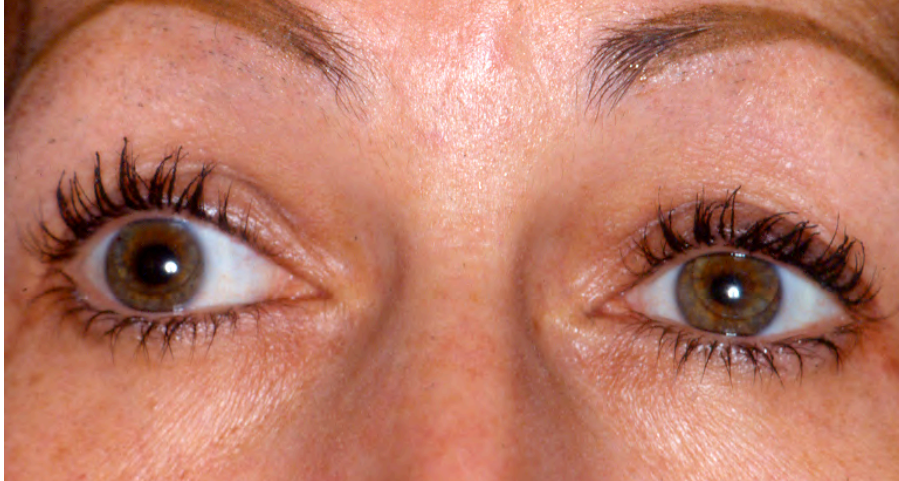Pupil enlargement in addition to lid droop and eye muscle weakness may signal an aneurysm and is a medical emergency. The patient should immediately have neuro-imaging (CT, MRI, MRA, and/or angiogram) to look for the aneurysm.



IIIrd Nerve Damage With Pupil Enlargement

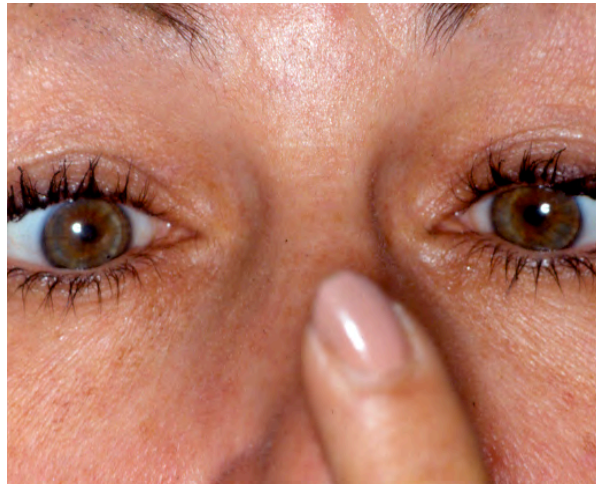When only the pupil portion of the IIIrd nerve is not working, the pupil is large and does not constrict in bright light. This might be caused by a medicine or chemical that dilates the pupil. Examples include motion-sickness patches, chemicals used in the garden, and certain eye drops. The patient often is unaware of what she touched that caused the problem but careful questioning by the doctor may reveal the cause. A pupil that is chemically dilated will return to normal size as the chemical wears off and eventually will react normally to light. Depending on the specific chemical, this can take hours or days.

Adie Pupil is another type of pupil that is large and constricts poorly in light.



Adie Pupil

An eye with an Adie pupil initially has difficulty focusing on objects held close, for example, for reading. Adie pupil is commonly seen in young adult women but men can develop it, too. In most cases, the cause of the damage is unknown and radiology studies rarely show any abnormality. A person can have Adie pupils in one or both eyes. Adie syndrome is the combination of Adie pupils and reduced reflexes such as knee jerks. The cause of Adie syndrome, like Adie pupil, is unknown. There is no treatment for Adie pupils. With time, the ability to focus up close usually returns. The Adie pupil may remain enlarged but more often shrinks in size gradually over several years, even becoming smaller than the normal pupil in the other eye. The Adie pupil will never react well to a light shined in the eye. It is important that you remember this for future eye exams.



Recovered Ability to Focus Up Close

Frequently Asked Questions

If uneven pupils are found, what can I do to help my doctor determine the cause?

Knowing how long the pupils have been unequal is very helpful. Bring old photographs to your appointment that show your pupils well (without camera “red eye”), such as childhood school pictures.

If I have a Horner Syndrome, how can I tell what is wrong?

A stroke has other neurologic symptoms, and can be seen by MRI imaging of the brain. A lung tumor can be seen on imaging of the chest. A carotid dissection can be seen by MRA imaging of the blood vessels in the neck. Your doctor will evaluate your history and all of your symptoms together to determine the appropriate imaging study to do.

My doctor has told me I had a carotid dissection. How did that happen? What can I expect?

A carotid dissection is a tear in the wall of one of the large arteries going to the brain. A dissection can be caused even by minor trauma such as turning the neck while swimming or parking a car. Carotid dissections usually heal on their own, but you will probably be given a blood thinner to reduce the chances of blockage of the artery or blood clots circulating to the brain or lungs.

I am a nurse working in the surgery department, and my doctor told me my enlarged pupil was caused by the atropine I administer to patients in pre-op. How can I prevent this from happening in the future?

Wash your hands, not only before and after touching the patient, but also after drawing up medications and touching the tubing used for IV administration of medications and after removing your gloves. Don't rub your eyes unless you are sure your hands are free of contamination.

What can I do to help focus up close if I have an Adie pupil?

Most patients with Adie pupil don't have any problem with this, but if you do, your doctor may be able to prescribe reading glasses that will help.

I have an Adie pupil. What can I do to prevent the other eye from being affected?

We often don't know what causes Adie pupil. Sometimes it follows a virus, and the other eye will probably not be affected. Sometimes it has no recognizable cause, but the other eye is affected, though sometimes it may be years later. We do not know of any way to prevent this.